

Vent. rate 81 BPM
 PR interval 120 ms
 QRS duration 80 ms
 QT/QTc 376/436 ms
 P-R-T axes 81 80 73

*** Leeftijds en geslacht specifieke ECG analyse ***
 Normaal sinusritme
 Normaal ECG
 Geen oud ECG aanwezig

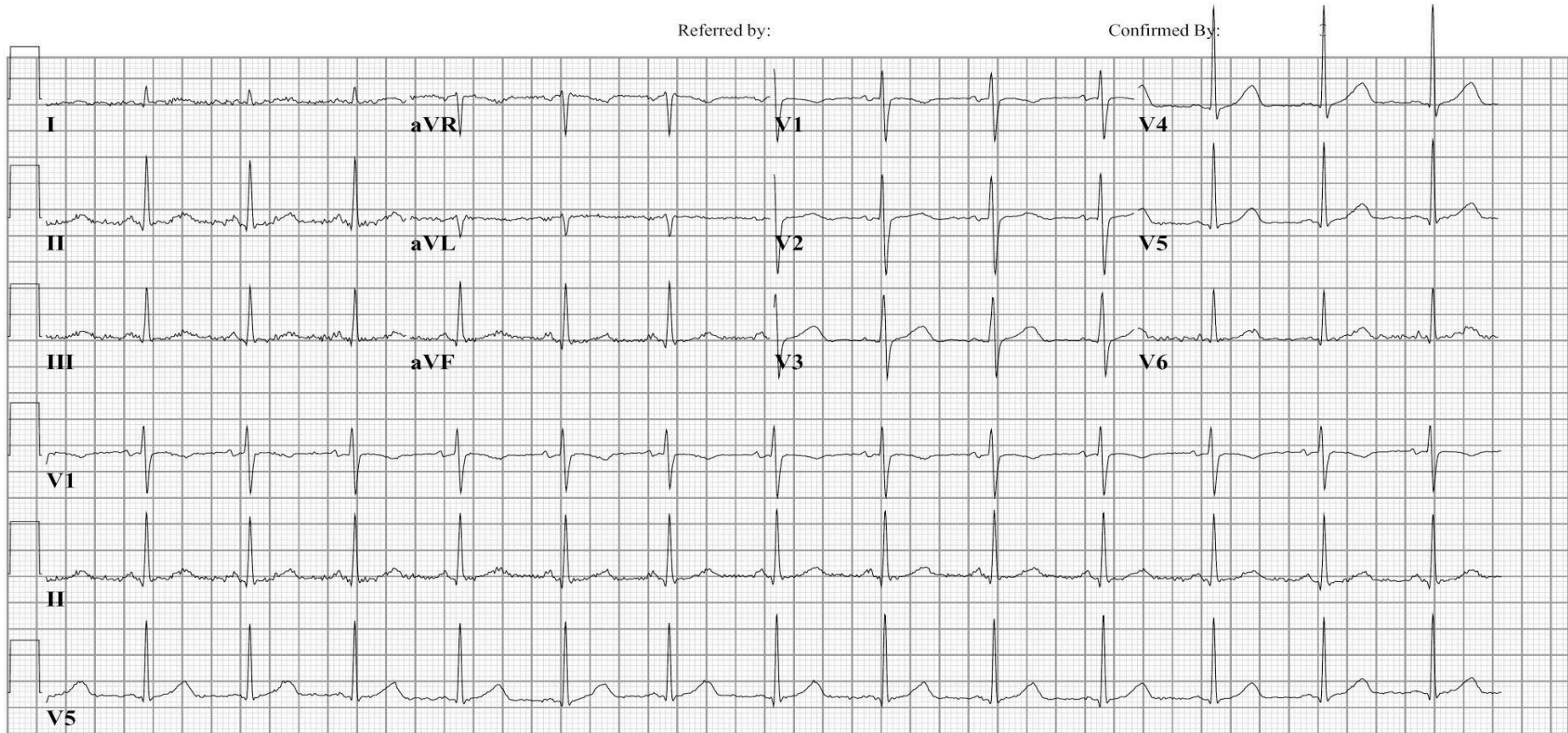
Image used with permission
 from ECGpedia.org

Loc:23

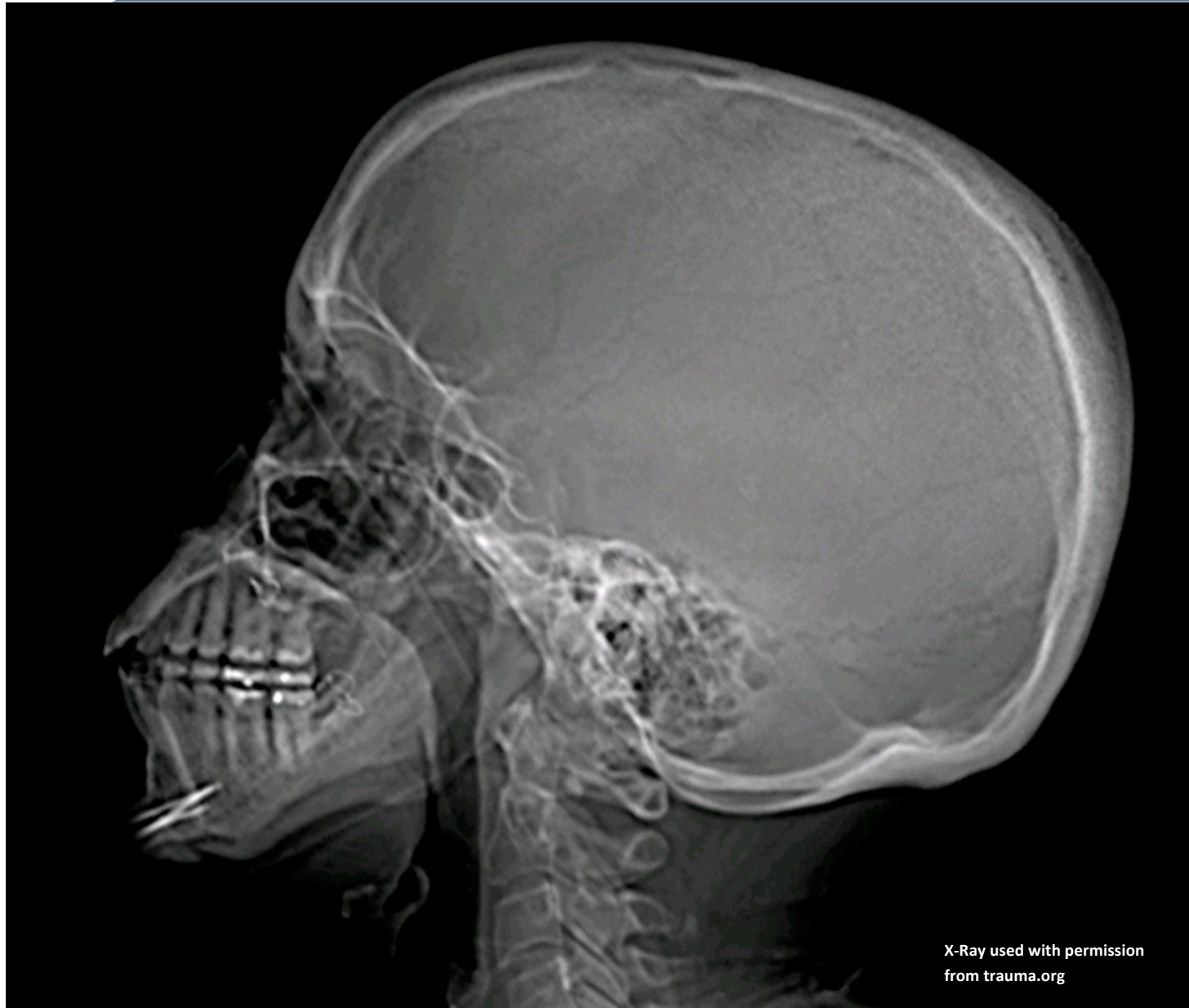
Technician:

Referred by:

Confirmed By:



25mm/s 10mm/mV 40Hz 005E 12SL 233 CID: 10



X-Ray used with permission from trauma.org

This project was possible due to funding made available by Health Workforce Australia